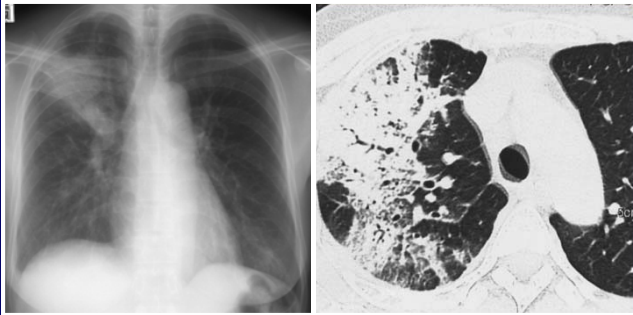
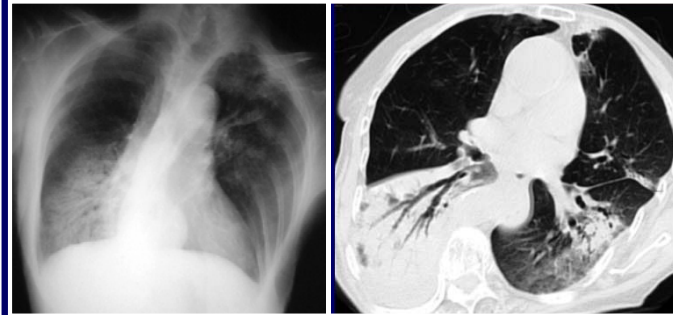


誤嚥性肺炎の画像は多彩である

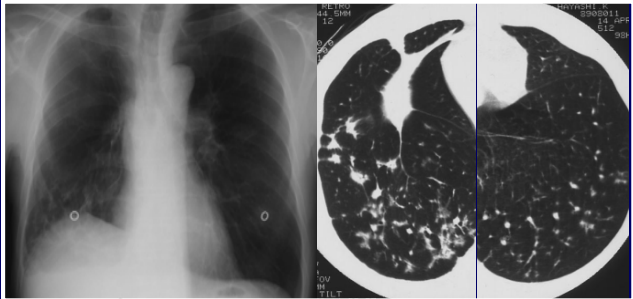
器質化肺炎パターン



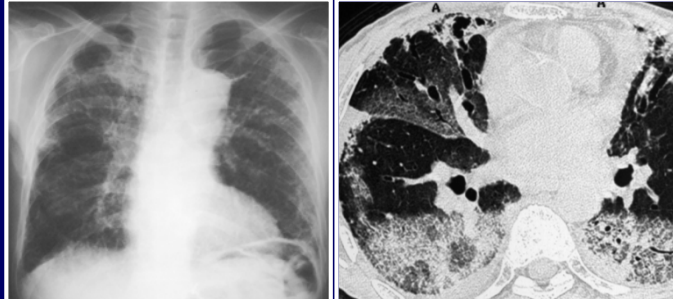
大葉性肺炎型



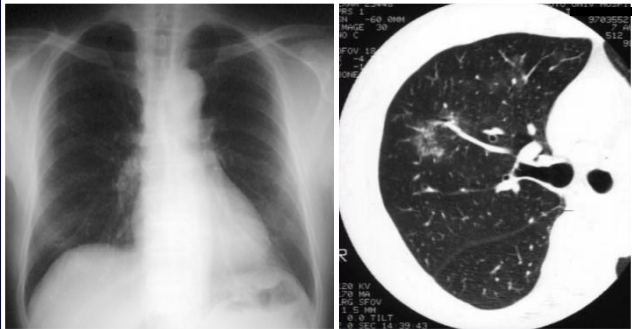
小葉中心性分布



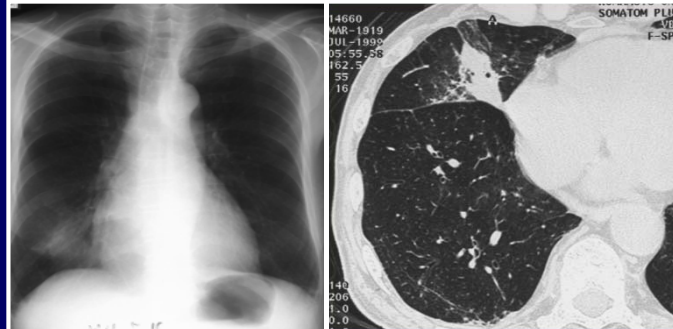
ARDSパターン(Mendelson症候群様)



気管支肺炎型



結節型



熊本大学呼吸器内科 (1996-2002)

