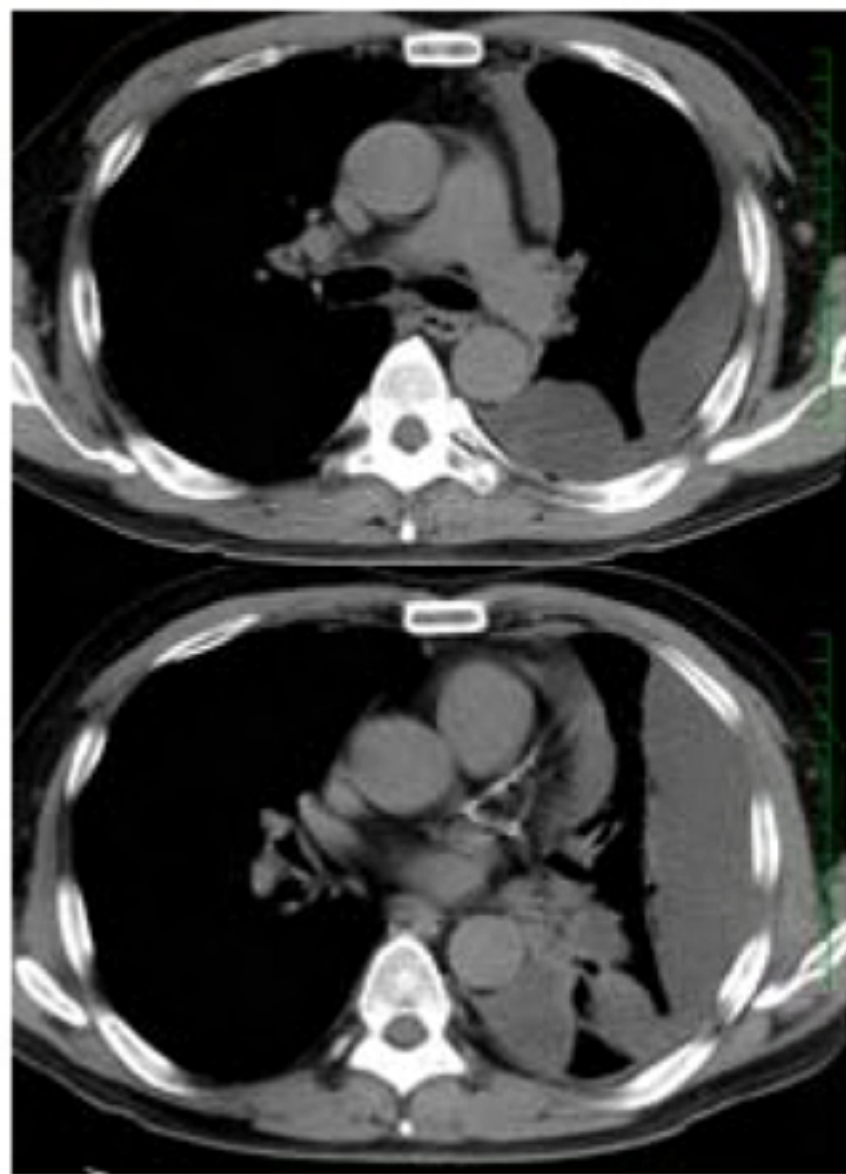
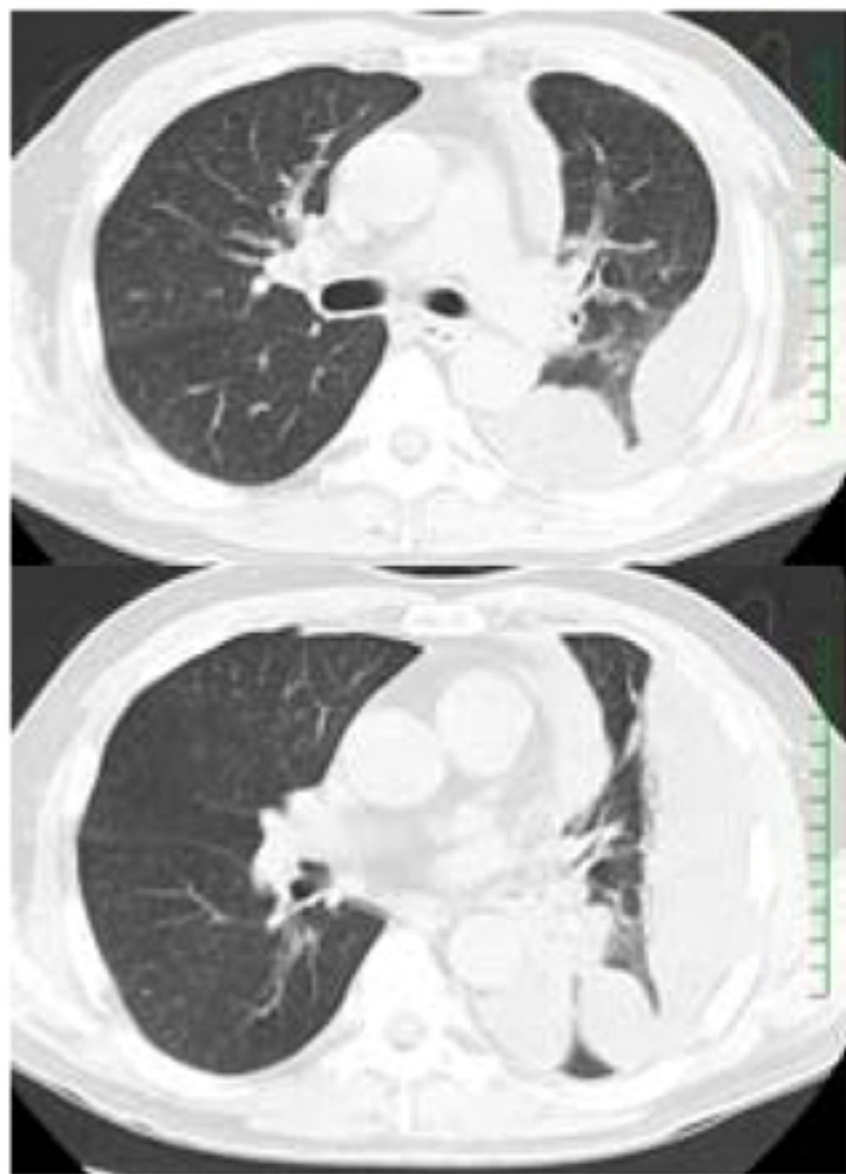


入院時胸部CT



被包化胸水